

DONALD A. NEUMANN, PT, PhD, FAPTA<sup>1</sup>

## Kinesiology of the Hip: A Focus on Muscular Actions

**T**he hip joint serves as a central pivot point for the body as a whole. This large ball-and-socket joint allows simultaneous, triplanar movements of the femur relative to the pelvis, as well as the trunk and pelvis relative to the femur. Lifting the foot off the ground, reaching towards the floor, or rapidly rotating the trunk and pelvis while supporting the body over one limb typically demands strong and specific activation of the hips' surrounding musculature.

Pathology that affects the strength, control, or extensibility of the hip muscles can significantly disrupt the fluidity, comfort, and metabolic efficiency of many routine movements involving both functional and recreational activities. Furthermore, abnormal performance of the muscles of the hip may alter the distribution of forces across the joint's articular surfaces, potentially causing, or at least predisposing, degenerative changes in the articular cartilage, bone, and surrounding connective tissues.

Physical therapy diagnosis related to

the hip and adjacent regions often requires a solid understanding of the actions of the surrounding muscles. This knowledge is instrumental in identifying when a specific muscle or muscle group is weak, painful, dominant, or tight (ie, lacks the extensibility to permit normal range of motion). Depending on the particular muscle, any one of these conditions can significantly affect the alignment across the lumbar spine, pelvis, and femur, ultimately affecting the alignment throughout the entire lower limb. Furthermore, understanding the actions of the hip

muscles is fundamental to interventions used to specifically activate, strengthen, or stretch certain muscles.

The primary purpose of this paper is to review and analyze the actions of the muscles of the hip. The discussion will include several topics associated with muscular kinesiology, including a muscle's torque (strength) potential, moment arm (ie, leverage), cross-sectional area, overall fiber direction, and line of force relative to an axis of rotation. When available, data from the research literature will be cited. As will be pointed out, some actions of muscles are strongly supported by rigorous research, while others are not.

### Line of Force

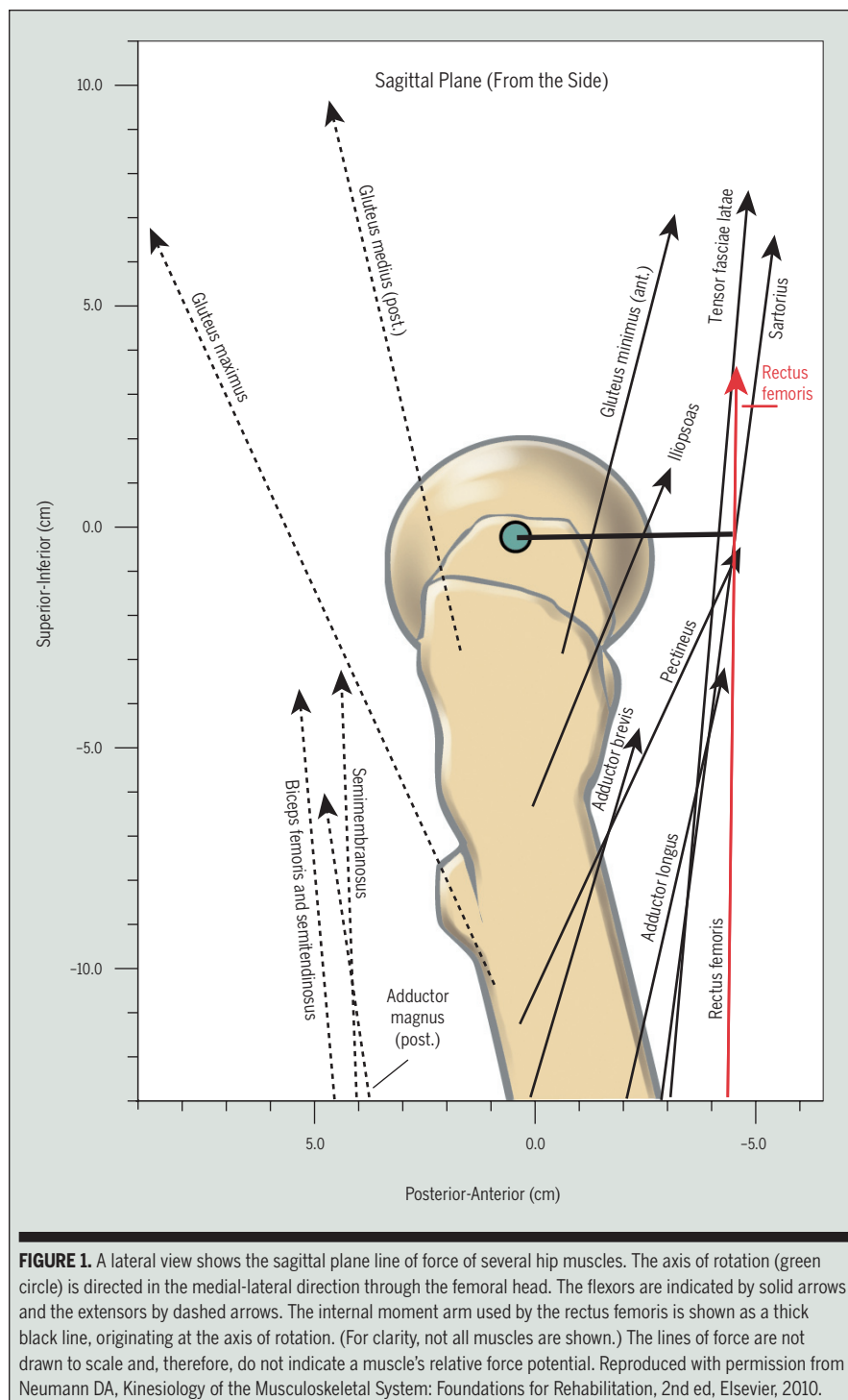
The discussion of muscle action will be organized according to the 3 cardinal planes of motion of the hip: sagittal, horizontal, and frontal. For each plane of motion, a muscle's action is based primarily on the orientation of its line of force relative to the joint's axis of rotation. **FIGURE 1** illustrates this orientation for several muscles acting within the sagittal plane. This figure, based on a straight-line model of muscle action, stems from the work of Dostal and others.<sup>16,17</sup> Using a male cadaver, the proximal and distal attachments of the muscles were carefully dissected and then digitized. A straight line between the attachment points was used to represent the muscle's line of force. Observe in **FIGURE 1**, for instance, that a muscle's line of force that passes anterior to the joint's medial-lateral axis of rota-

• **SYNOPSIS:** The 21 muscles that cross the hip provide both triplanar movement and stability between the femur and acetabulum. The primary intent of this clinical commentary is to review and discuss the current understanding of the specific actions of the hip muscles. Analysis of their actions is based primarily on the spatial orientation of the muscles relative to the axes of rotation at the hip. The discussion of muscle actions is organized according to the 3 cardinal planes of motion. Actions are considered from both femoral-on-pelvic and pelvic-on-femoral perspectives, with particular attention to the role of coactivation of trunk muscles. Additional attention is paid to the biomechanical variables that alter the effective-

ness, force, and torque of a given muscle action. The role of certain muscles in generating compression force at the hip is also presented. Throughout the commentary, the kinesiology of the muscles of the hip are considered primarily from normal but also pathological perspectives, supplemented with several clinically relevant scenarios. This overview should serve as a foundation for understanding the assessment and treatment of musculoskeletal impairments that involve not only the hip, but also the adjacent low back and knee regions. *J Orthop Sports Phys Ther* 2010;40(2):82-94. doi:10.2519/jospt.2010.3025

• **KEY WORDS:** adductor magnus, biomechanics, gluteus maximus, gluteus medius, hip

<sup>1</sup>Professor, Physical Therapy Department, Marquette University, Milwaukee, WI. Address correspondence to Dr Donald A. Neumann, Marquette University, Physical Therapy Department, Walter Schroeder Complex, Rm 346, PO Box 1881, Milwaukee, WI 53201-1881. E-mail: donald.neumann@marquette.edu



**FIGURE 1.** A lateral view shows the sagittal plane line of force of several hip muscles. The axis of rotation (green circle) is directed in the medial-lateral direction through the femoral head. The flexors are indicated by solid arrows and the extensors by dashed arrows. The internal moment arm used by the rectus femoris is shown as a thick black line, originating at the axis of rotation. (For clarity, not all muscles are shown.) The lines of force are not drawn to scale and, therefore, do not indicate a muscle's relative force potential. Reproduced with permission from Neumann DA, *Kinesiology of the Musculoskeletal System: Foundations for Rehabilitation*, 2nd ed, Elsevier, 2010.

tion would be characterized as a flexor (such as the highlighted rectus femoris); conversely, a muscle's line of force passing posterior to the same axis would be characterized as an extensor. This visual perspective not only strongly suggests a

muscle's action but, equally important, indicates the relative moment arm length (leverage) available to generate the torque for the particular action. The original data used to generate **FIGURE 1** is listed in **TABLE 1**.<sup>17</sup> This table shows, for example,

that the rectus femoris has a 4.3-cm moment arm for flexion, along with a 0.2-cm moment arm for external rotation, and a 2.3-cm moment arm for abduction.

The work by Dostal et al<sup>16,17</sup> is highlighted throughout this paper because it applies to all hip muscles across all 3 planes of motion. No other single source of such extensive data could be located. Extrapolating Dostal et al's<sup>16,17</sup> work to the general population requires caution, however, because the data represent only 1 (male) cadaver specimen and are based on a relatively simple straight-line model. Nevertheless, the data do provide valuable insight into a critical variable that determines a muscle's action. Additional published data of this type is needed to more adequately reflect the complex shape of many muscles and the anthropometric differences based on gender, age, body size, and natural variability.

Based on information published in the literature and cadaver and skeletal inspection, the muscles of the hip will be designated as being primary or secondary for a given action (**TABLE 2**). Some muscles have only a marginal potential to produce a particular action, due to factors such as negligible moment arm length or small cross-sectional area. Muscles that likely have an insignificant action will not be considered in the discussion.

### Muscle Action Versus Muscle Torque

Although the visual representation of **FIGURE 1** is useful for assessing a muscle's potential action within a given plane, 2 limitations must be recognized. First, the figure lacks information to indisputably rank the muscle's relative torque potential within a given plane. A muscle torque and a muscle action are indeed different. While a muscle action describes the potential direction of rotation of the joint following its activation by the nervous system, a muscle torque describes the "strength" of the action. A muscle torque can be estimated by the product of the muscle force (in Newtons) within a plane of interest and the muscle's associated moment arm length (in centimeters). Both

TABLE 1

LIST OF MOMENT ARM DATA (CM) FOR THE MUSCLES OF THE HIP, CATEGORIZED BY THEIR POTENTIAL ACTION IN THE SAGITTAL, HORIZONTAL, AND FRONTAL PLANES<sup>17\*</sup>

Muscle	Sagittal Plane	Horizontal Plane	Frontal Plane
Adductor brevis	F: 2.1	IR: 0.5	Ad: 7.6
Adductor longus	F: 4.1	IR: 0.7	Ad: 7.1
Adductor magnus (anterior head)	E: 1.5	ER: 0.2	Ad: 6.9
Adductor magnus (posterior head)	E: 5.8	IR: 0.4	Ad: 3.4
Biceps femoris	E: 5.4	ER: 0.6	Ad: 1.9
Gemellus inferior	E: 0.4	ER: 3.3	Ad: 0.9
Gemellus superior	E: 0.3	ER: 3.1	Ab: 0.1
Gluteus maximus	E: 4.6	ER: 2.1	Ad: 0.7
Gluteus medius (anterior fibers)	E: 0.8	IR: 2.3	Ab: 6.7
Gluteus medius (middle fibers)	E: 1.4	IR: 0.1	Ab: 6.0
Gluteus medius (posterior fibers)	E: 1.9	ER: 2.4	Ab: 4.3
Gluteus minimus (anterior fibers)	F: 1.0	IR: 1.7	Ab: 5.8
Gluteus minimus (middle fibers)	F: 0.2	ER: 0.3	Ab: 5.3
Gluteus minimus (posterior fibers)	E: 0.3	ER: 1.4	Ab: 3.9
Gracilis	F: 1.3	ER: 0.3	Ad: 7.1
Iliopsoas	F: 1.8	IR: 0.5	Ab: 0.7
Obturator externus	F: 0.7	ER: 0.4	Ad: 2.4
Obturator internus	E: 0.3	ER: 3.2	Ad: 0.7
Pectineus	F: 3.6	IR: 1.0	Ad: 3.2
Piriformis	E: 0.1	ER: 3.1	Ab: 2.1
Quadratus femoris	E: 0.2	ER: 3.4	Ad: 4.4
Rectus femoris	F: 4.3	ER: 0.2	Ab: 2.3
Sartorius	F: 4.0	ER: 0.3	Ab: 3.7
Semimembranosus	E: 4.6	IR: 0.3	Ad: 0.4
Semitendinosus	E: 5.6	IR: 0.5	Ad: 0.9
Tensor fascia latae	F: 3.9	0.0	Ab: 5.2

Abbreviations: Ab, abduction; Ad, adduction; E, extension; ER, external rotation; F, flexion; IR, internal rotation.

\* Muscles are presented in alphabetical order. Data are based on the male cadaver specimen being oriented in the anatomic position.

tions described for **FIGURE 1** are respected, the associated method of visual analysis can provide a very useful and logical mental construct for considering a muscle's potential action, as well as peak strength, assuming maximal force production.

## SAGITTAL PLANE

### Hip Flexors

**F**IGURE 1 DEPICTS MUSCLES THAT FLEX the hip and **TABLE 2** lists the actions of these and other muscles as either primary or secondary. One of the more prominent hip flexor muscles is the iliopsoas. This thick muscle produces a force across the hip, sacroiliac joint, lumbosacral junction, and lumbar spine.<sup>18,41,52</sup> Because the muscle spans both the axial and appendicular components of the skeleton, it is a hip flexor as well as a trunk flexor. In addition, the psoas major affords an important element of vertical stability to the lumbar spine, especially when the hip is in full extension and passive tension is greatest in the muscle.<sup>52</sup>

The conjoined distal tendon of the iliacus and the psoas major crosses anterior and slightly medial to the femoral head, as it courses toward its insertion on the lesser trochanter. During this distal path, the broad tendon is deflected posteriorly about 35° to 45° as it crosses the superior pubic ramus of the pubis. With the hip in full extension, this deflection raises the tendon's angle-of-insertion relative to the femoral head, thereby increasing the muscle's leverage for hip flexion. As the hip flexes to 90°, the flexion leverage becomes even greater.<sup>8</sup> Such a parallel increase in leverage with increased flexion may partially offset the muscle's potential loss in active force (and ultimately torque) caused by its reduced length.

Theoretically, a sufficiently strong and isolated bilateral contraction of any hip flexor muscle will either rotate the femur toward the pelvis, the pelvis (and possibly the trunk) towards the femur, or both actions simultaneously. These kinematics occur within the sagittal plane about a medial-lateral axis of rotation through

variables of force and moment arm are equally important when estimating the potential torque output, or strength, of a muscle. Although **FIGURE 1** is constructed to appreciate a muscle's likely action and relative moment arm length, it does not indicate the muscle's force potential. The arrows used in the figure are not vectors and are not drawn to scale. The orientation of the arrows represents only the assumed linear direction of the force, not its amplitude. Estimating a muscle's force requires other information, such as its cross-sectional area.

The second limitation of **FIGURE 1** is

that the lines of force of the muscles and the lengths of the moment arms apply only to the anatomic position. Once moved out of this position, the variables that affect a muscle's action and torque potential change.<sup>8</sup> These changes partially explain why maximal-effort torque and, in some cases, even a muscle's action vary across the full range of hip motion. Unless otherwise specified, the actions of the muscles of the hip discussed in this paper are based upon a contraction that has occurred from the anatomic position.

Provided the aforementioned limita-

TABLE 2

## MUSCLES OF THE HIP, ORGANIZED ACCORDING TO PRIMARY OR SECONDARY ACTIONS\*

Muscles	Primary	Secondary
Flexors	<ul style="list-style-type: none"> <li>Iliopsoas</li> <li>Sartorius</li> <li>Tensor fasciae latae</li> <li>Rectus femoris</li> <li>Adductor longus</li> <li>Pectineus</li> </ul>	<ul style="list-style-type: none"> <li>Adductor brevis</li> <li>Gracilis</li> <li>Gluteus minimus (anterior fibers)</li> </ul>
Extensors	<ul style="list-style-type: none"> <li>Gluteus maximus</li> <li>Adductor magnus (posterior head)</li> <li>Biceps femoris (long head)</li> <li>Semitendinosus</li> <li>Semimembranosus</li> </ul>	<ul style="list-style-type: none"> <li>Gluteus medius (middle and posterior fibers)</li> <li>Adductor magnus (anterior head)</li> </ul>
External rotators	<ul style="list-style-type: none"> <li>Gluteus maximus</li> <li>Piriformis</li> <li>Obturator internus</li> <li>Gemellus superior</li> <li>Gemellus inferior</li> <li>Quadratus femoris</li> </ul>	<ul style="list-style-type: none"> <li>Gluteus medius (posterior fibers)</li> <li>Gluteus minimus (posterior fibers)</li> <li>Obturator externus</li> <li>Sartorius</li> <li>Biceps femoris (long head)</li> </ul>
Internal rotators	Not applicable	<ul style="list-style-type: none"> <li>Gluteus minimus (anterior fibers)</li> <li>Gluteus medius (anterior fibers)</li> <li>Tensor fasciae latae</li> <li>Adductor longus</li> <li>Adductor brevis</li> <li>Pectineus</li> <li>Adductor magnus (posterior head)</li> </ul>
Adductors	<ul style="list-style-type: none"> <li>Pectineus</li> <li>Adductor longus</li> <li>Gracilis</li> <li>Adductor brevis</li> <li>Adductor magnus (anterior and posterior heads)</li> </ul>	<ul style="list-style-type: none"> <li>Biceps femoris (long head)</li> <li>Gluteus maximus (posterior fibers)</li> <li>Quadratus femoris</li> <li>Obturator externus</li> </ul>
Abductors	<ul style="list-style-type: none"> <li>Gluteus medius (all fibers)</li> <li>Gluteus minimus (all fibers)</li> <li>Tensor fasciae latae</li> </ul>	<ul style="list-style-type: none"> <li>Piriformis</li> <li>Sartorius</li> <li>Rectus femoris</li> </ul>

\* Each action assumes a muscle is fully activated from the anatomic position. Several of these muscles may have a different action when they are activated outside of this reference position.

the femoral heads. Note that the arrowhead representing the line of force of the rectus femoris in **FIGURE 1**, for example, is directed upward, toward the pelvis. This convention is used throughout this paper and assumes that at the instant of muscle contraction, the pelvis is more physically stabilized than the femur. If the pelvis is inadequately stabilized by other muscles, a sufficiently strong force from the rectus femoris (or any other hip flexor muscle) could rotate or tilt the pelvis anteriorly. In this case, the arrowhead of the rectus femoris would logically be pointed downward toward the relatively fixed femur.

The discussion above helps to explain why a person with weakened abdominal muscles may demonstrate, while actively contracting the hip flexors muscles, an

undesired and excessive anterior tilting of the pelvis. Normally, moderate to high hip flexion effort is associated with relatively strong activation of the abdominal muscles.<sup>22</sup> This intermuscular cooperation is very apparent while lying supine and performing a straight leg raise movement. The abdominal muscles must generate a potent posterior pelvic tilt of sufficient force to neutralize the strong anterior pelvic tilt potential of the hip flexor muscles. This synergistic activation of the abdominal muscles is demonstrated by the rectus abdominis (**FIGURE 2A**). The extent to which the abdominal muscles actually neutralize and prevent an anterior pelvic tilt is dependent on the demands of the activity—for example, of lifting 1 or both limbs—and the relative strength of the

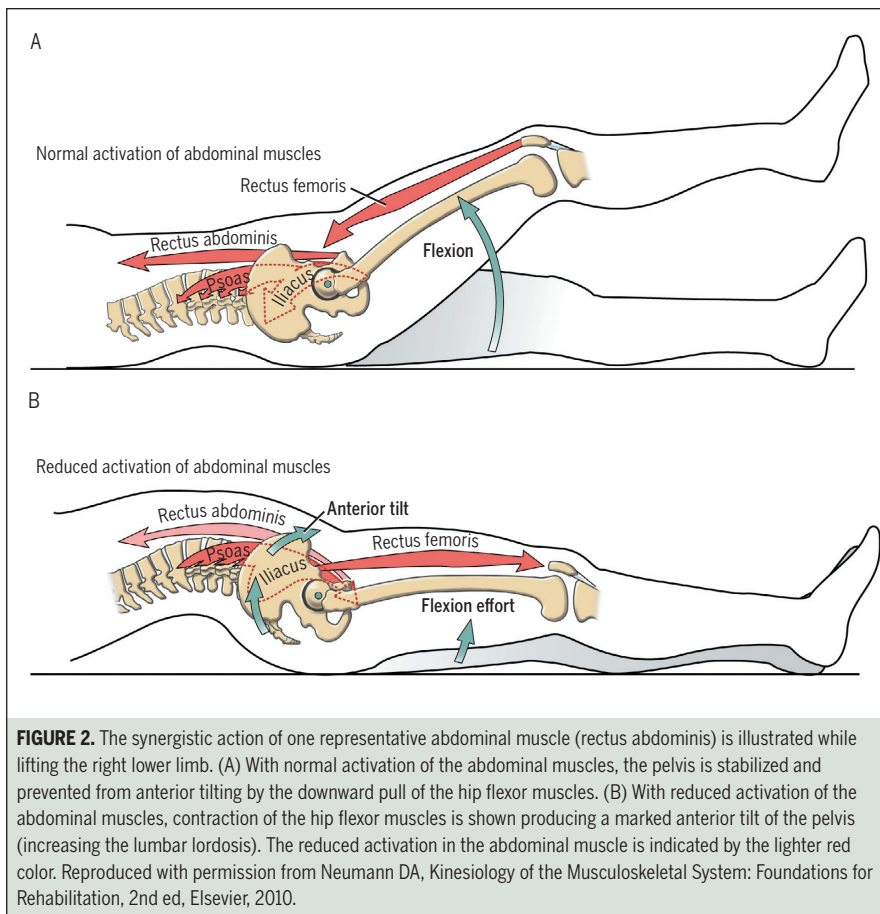
contributing muscle groups.<sup>14</sup> Rapid flexion of the hip is generally associated with abdominal muscle activation that slightly precedes the activation of the hip flexor muscles.<sup>22</sup> This anticipatory activation has been shown to be most dramatic and consistent in the transverse abdominis, at least in healthy subjects without low back pain.<sup>40</sup> The consistently early activation of the transverse abdominis may reflect a feedforward mechanism intended to stabilize the lumbopelvic region by increasing intra-abdominal pressure and increasing the tension in the thoracolumbar fascia.<sup>21,46</sup>

Without sufficient stabilization of the pelvis by the abdominal muscles, a strong contraction of the hip flexor muscles may inadvertently tilt the pelvis anteriorly (**FIGURE 2B**). An excessive anterior tilt of the pelvis typically accentuates the lumbar lordosis. This posture may contribute to low back pain in some individuals.

Although **FIGURE 2B** highlights the unopposed contraction of 3 of the more recognizable hip flexor muscles, the same principle can be applied to all hip flexor muscles. Any muscle that is capable of flexing the hip from a femoral-on-pelvic perspective has a potential to flex the hip from a pelvic-on-femoral rotation. For this reason, tightness of secondary hip flexors, such as adductor brevis, gracilis, and anterior fibers of the gluteus minimus, would, in theory, contribute to an excessive anterior pelvic tilt and exaggerated lumbar lordosis.

### Hip Extensors

The primary hip extensors include the gluteus maximus, posterior head of the adductor magnus, and the hamstrings (**TABLE 2**).<sup>13,17</sup> In the anatomic position, the posterior head of the adductor magnus has the greatest moment arm for extension, followed closely by the semitendinosus.<sup>17</sup> The moment arm for both of these extensor muscles increases as the hip is flexed to 60°. <sup>39</sup> According to Winter,<sup>50</sup> the gluteus maximus and adductor magnus have the greatest cross-sectional areas of all the primary extensors. The middle and



**FIGURE 2.** The synergistic action of one representative abdominal muscle (rectus abdominis) is illustrated while lifting the right lower limb. (A) With normal activation of the abdominal muscles, the pelvis is stabilized and prevented from anterior tilting by the downward pull of the hip flexor muscles. (B) With reduced activation of the abdominal muscles, contraction of the hip flexor muscles is shown producing a marked anterior tilt of the pelvis (increasing the lumbar lordosis). The reduced activation in the abdominal muscle is indicated by the lighter red color. Reproduced with permission from Neumann DA, *Kinesiology of the Musculoskeletal System: Foundations for Rehabilitation*, 2nd ed, Elsevier, 2010.

posterior fibers of the gluteus medius and anterior head of the adductor magnus are considered secondary extensors.<sup>16</sup>

The hip extensor muscles, as a group, produce the greatest torque across the hip than any other muscle group (FIGURE 3).<sup>10</sup> The extensor torque is often used to rapidly accelerate the body upward and forward from a position of hip flexion, such as when pushing off into a sprint, arising from a deep squat, or climbing a very steep hill. The position of flexion naturally augments the torque potential of the hip extensor muscles.<sup>5,23,34</sup> Furthermore, with the hip markedly flexed, many of the adductor muscles produce an extension torque, thereby assisting the primary hip extensors.<sup>23</sup>

With the trunk held relatively stationary, contraction of the hip extensors and abdominal muscles (with the exception of the transverse abdominis<sup>22</sup>) functions as a force-couple to posteriorly tilt the pel-

vis (FIGURE 4). A posterior tilting motion of the pelvis is actually a short-arc, bilateral (pelvic-on-femoral) hip extension movement. Both right and left acetabula rotate in the sagittal plane, relative to the fixed femoral heads, about a medial-lateral axis of rotation. Assuming the trunk remains upright during this action, the lumbar spine must flex slightly, reducing its natural lordotic posture.

While standing, the performance of a full posterior pelvic tilt, theoretically, increases the tension in the hip's capsular ligaments and hip flexor muscles. These tissues, if tight, can potentially limit the end range of an active posterior pelvic tilt. Contraction of the abdominal muscles (acting as short-arc hip extensors, as depicted in FIGURE 4) can, theoretically, assist other hip extensor muscles in elongating (stretching) a tight hip capsule or hip flexor muscle. For example, strongly coactivating the abdominal and gluteal

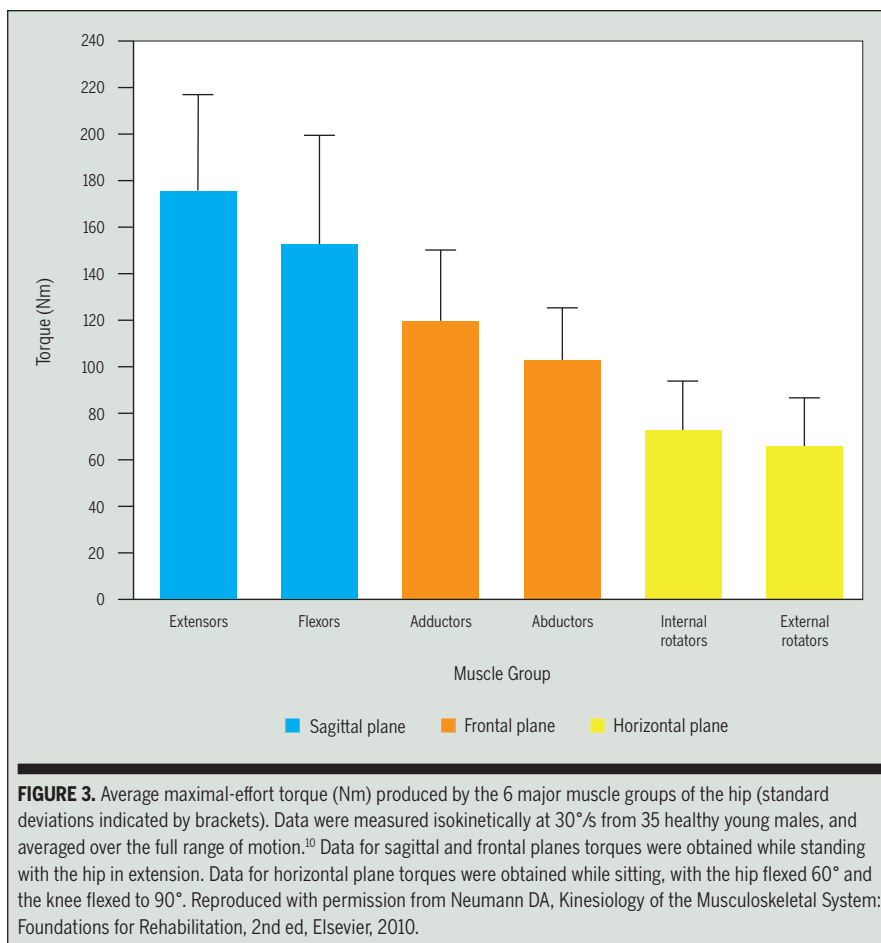
muscles, while simultaneously performing a traditional passive-stretching maneuver of the hip flexor muscles, may provide an additional stretch to these muscles. One underlying advantage of this therapeutic approach is that it may actively engage and potentially educate the patient about controlling the biomechanics of this region of the body.

Achieving near full extension of the hips has important functional advantages, such as increasing the metabolic efficiency of relaxed stance and walking.<sup>11</sup> Full or nearly full hip extension allows a person's line of gravity to pass just posterior to the medial-lateral axis of rotation through the femoral heads. Gravity, in this case, can assist with maintaining the extended hip while standing, with little activation from the hip extensor muscles. Because the hip's capsular ligaments naturally become "wound up" and relatively taut in full extension, an additional element of passive extension torque, albeit relatively small, may further assist with the ease of standing. This biomechanical situation may be beneficial by temporarily reducing the metabolic demands on the muscles but also by reducing the joint reaction forces across the hips due to muscle activation, at least for short periods.

## HORIZONTAL PLANE

### Hip External Rotators

**F**IGURE 5 SHOWS A SUPERIOR VIEW OF the lines of force of several external and internal rotators of the hip. The external rotator muscles (depicted as solid arrows) pass generally posterior-lateral to the joint's longitudinal (or vertical) axis of rotation. Because the vertical axis of rotation remains roughly aligned with the femur, it is only truly vertical near the anatomic position. The muscles considered as primary external rotators include the gluteus maximus and 5 of the 6 short external rotators (TABLE 2). From the anatomic position, the secondary external rotators include the posterior fibers of the gluteus medius and minimus, obturator

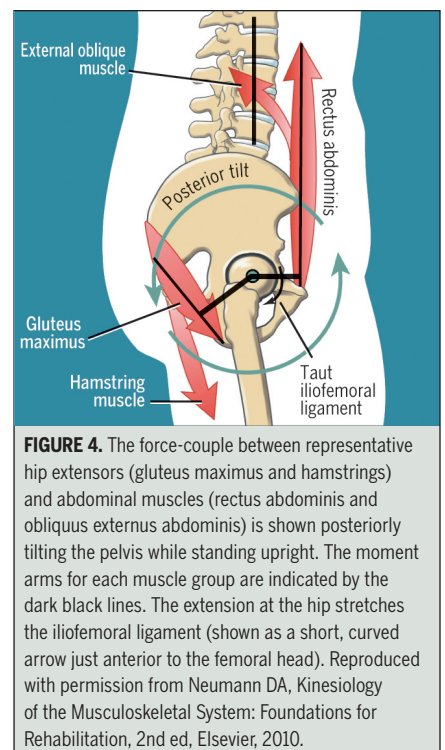


externus, sartorius, and the long head of the biceps femoris. The obturator externus is considered a secondary rotator because its line of force lies so close to the longitudinal axis of rotation (FIGURE 5). In general, any muscle with a line of force that either passes through or parallels the axis of rotation cannot develop a torque. In a few degrees of hip internal rotation, it is likely that the line of force of the obturator externus would indeed pass through the longitudinal axis, thereby negating any torque potential in the horizontal plane.

The gluteus maximus is the most potent external rotator muscle of the hip.<sup>13</sup> This suitably named muscle is the largest muscle of the hip, accounting for about 16% of the total cross-sectional area of all hip musculature.<sup>50</sup> Assuming that the gluteus maximus muscle's line of force is directed approximately 45° with respect to

the frontal plane, maximal-effort activation would theoretically generate 71% of its total force within the horizontal plane (based on the sine or cosine of 45°). All of this force could theoretically be used to generate an external rotation torque.

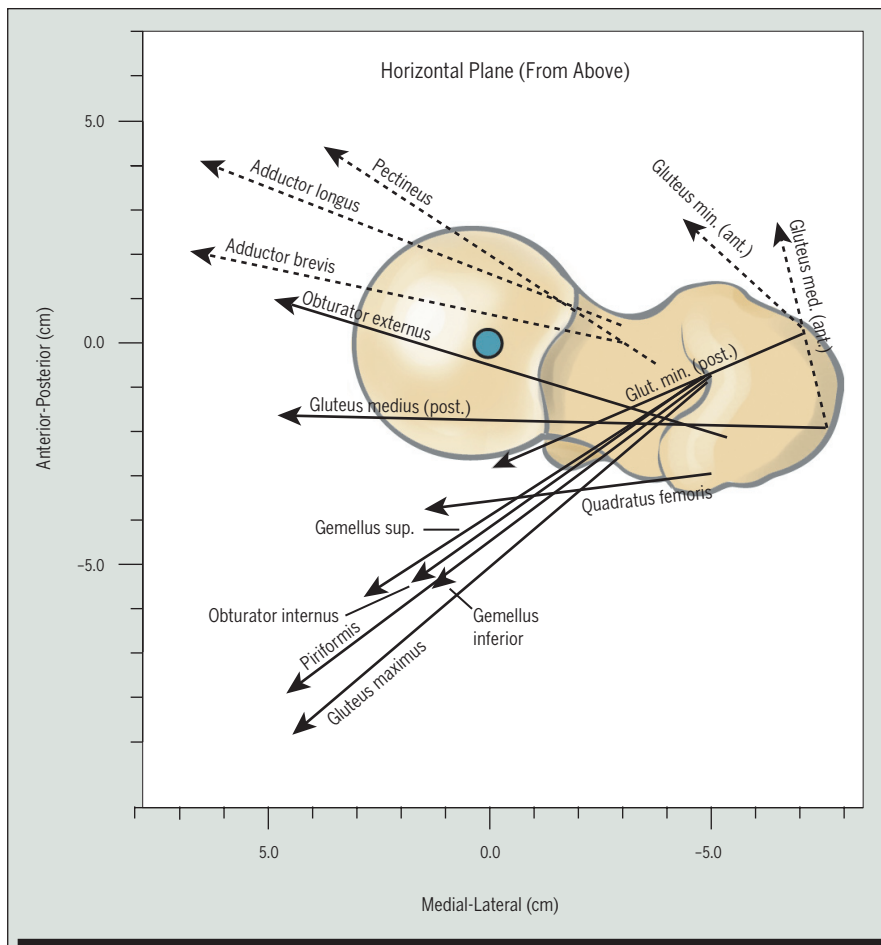
The short external rotator muscles are ideally designed to produce an effective external rotation torque. With the slight exception of the piriformis, the remaining short external rotators possess a near-horizontal line of force. This overall force vector makes a near-perpendicular intersection with the joint's longitudinal (vertical) axis of rotation. This being the case, nearly all of a given muscle's force is dedicated to producing external rotation torque. This force is also ideally aligned to compress the hip joint surfaces. In a manner generally similar to the infraspinatus and teres minor at the glenohumeral joint, the short external rotators of the



hip also likely provide an important element of mechanical stability to the acetabulofemoral articulation.

Interestingly, the popular posterior surgical approach to a total hip arthroplasty used by some surgeons necessarily cuts through at least part of the hip's posterior capsule, potentially disrupting several of the short external rotator tendons. Studies have reported a significant reduction in the incidence of posterior hip dislocation when the surgeon carefully repairs the posterior capsule and external rotator tendons.<sup>15,33,48</sup> Greater success of capsulotendinous reattachment has been more recently documented, purportedly as a result of using techniques that result in less disruption of the piriformis and most of the quadratus femoris.<sup>27</sup>

The functional potential of the entire external rotator muscle group is most fully recognized while performing pelvic and trunk rotational activities while bearing weight over 1 limb. With the right femur held relatively fixed, contraction of the external rotators would rotate the pelvis and the attached trunk to the left. This action of planting the limb and cutting



**FIGURE 5.** A superior view depicts the horizontal plane line of force of several muscles that cross the hip. The longitudinal axis of rotation (blue circle) passes through the femoral head in a superior-inferior direction. The external rotators are indicated by solid arrows and the internal rotators by dashed arrows. For clarity, not all muscles are shown. The lines of force are not drawn to scale and, therefore, do not indicate a muscle's relative force potential. Reproduced with permission from Neumann DA, *Kinesiology of the Musculoskeletal System: Foundations for Rehabilitation*, 2nd ed, Elsevier, 2010.

90° to 100°, the string now migrates to the opposite side of the longitudinal axis (which has moved with the flexed femur) to a position that would theoretically produce internal rotation. Using 4 cadaveric hip specimens and a computerized musculoskeletal model, Delp et al<sup>13</sup> reported that the piriformis possesses an external rotation moment arm of 2.9 cm with the hip in 0° of flexion but a 1.4-cm internal rotation moment arm with the hip in 90° of flexion. Assuming, for example, a near-maximum contractile force of 200 N, the muscle would theoretically produce 5.8 Nm of external rotation torque with the hip in neutral extension, but 2.8 Nm of internal rotation torque with the hip in 90° of flexion.

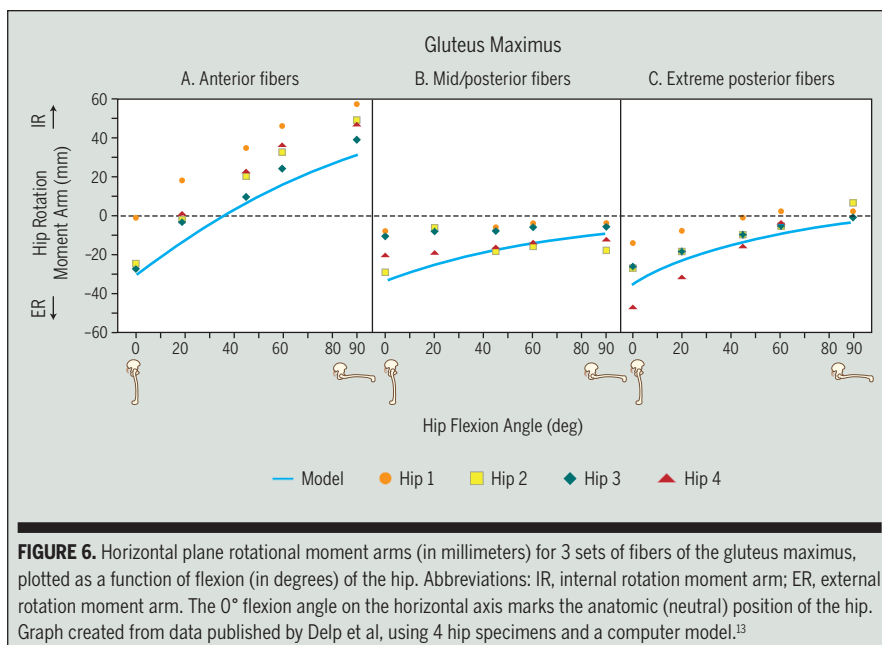
The exact point at which the 3 aforementioned traditional external rotator muscle fibers actually switch their rotary action is not fully understood, and this certainly varies between muscles, portions of a muscle, and subjects. Delp et al<sup>13</sup> provide data on the varying rotational moment arms throughout a sagittal plane arc for only a few muscles, including the gluteus maximus. **FIGURE 6A to 6C** shows the changing rotational moment arms for this muscle's anterior, mid-posterior, and extreme posterior fibers across an arc of 0° to 90° of flexion. As depicted in **FIGURE 6A**, considering both the model and the cadaver data, the gluteus maximus anterior fibers have an overall external rotation moment arm in a position of 0° of flexion. These same fibers, however, appear to switch their rotation action by about 45° of flexion; although the switch may only result in functionally significant internal rotation torque at flexion angles greater than 60° to 70°. The mid-posterior and extreme posterior fibers of the gluteus maximus (**FIGURE 6B** and **6C**) maintain an external rotation moment arm throughout virtually the entire measured range of flexion.

The rotational (horizontal plane) potential of the external rotator muscles as a function of the sagittal plane position of the hip requires a careful review of the entire set of data published by Delp et al.<sup>13</sup>

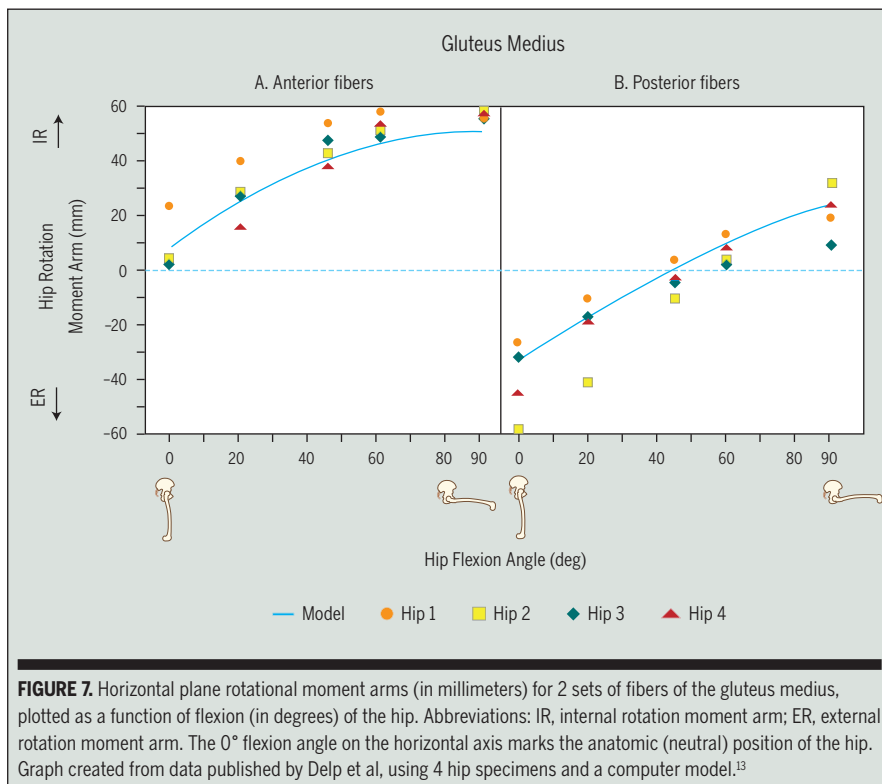
to the opposite side is a natural way to abruptly change direction while running. The gluteus maximus appears uniquely designed to perform this action. With the right limb securely planted, a strong contraction of the gluteus maximus would, in theory, generate a very effective extension and external rotation torque about the right hip, helping to provide the necessary thrust to the combined cutting-and-propulsion action. Dynamic stability of the hip during this high-velocity rotation may be one of the primary functions of the short external rotators.

Computer modeling and biomechanical studies demonstrate that the sagittal plane position of the hip can reverse the

horizontal plane actions of entire or, more often, parts of, external rotator muscles. Data indicate that the piriformis, posterior fibers of the gluteus minimus, and the anterior fibers of the gluteus maximus reverse their rotary action and become internal hip rotators as the hip is significantly flexed.<sup>13,17</sup> This concept can be elucidated with the aid of a skeleton model and a piece of string designed to mimic the line of force of a muscle. Consider the piriformis. With the hip in full extension, affixing the proximal and distal attachments of the string to the skeleton results in a muscular line of force that is posterior to the longitudinal axis of rotation. With the hip flexed to at least



**FIGURE 6.** Horizontal plane rotational moment arms (in millimeters) for 3 sets of fibers of the gluteus maximus, plotted as a function of flexion (in degrees) of the hip. Abbreviations: IR, internal rotation moment arm; ER, external rotation moment arm. The 0° flexion angle on the horizontal axis marks the anatomic (neutral) position of the hip. Graph created from data published by Delp et al, using 4 hip specimens and a computer model.<sup>13</sup>



**FIGURE 7.** Horizontal plane rotational moment arms (in millimeters) for 2 sets of fibers of the gluteus medius, plotted as a function of flexion (in degrees) of the hip. Abbreviations: IR, internal rotation moment arm; ER, external rotation moment arm. The 0° flexion angle on the horizontal axis marks the anatomic (neutral) position of the hip. Graph created from data published by Delp et al, using 4 hip specimens and a computer model.<sup>13</sup>

When reviewed for the gluteus maximus, as a whole, this large muscle is a potent external rotator, most notably at hip angles lower than 45° to 60° of flexion. There is, however, a noticeable shift in rotation potential that favors greater internal rota-

tion (or less external rotation) leverage at higher hip flexion angles, but only for the more anterior components of the muscle. Most of the gluteus maximus muscle maintains an external rotation moment arm throughout 0° to 90° of flexion.

A potential switch, or reversal, in a muscle's rotation action could affect the method used for its therapeutic stretching. Consider the piriformis, reportedly an external rotator in full extension but an internal rotator at 90° or more of flexion.<sup>13</sup> Restrictions in the extensibility of this muscle are typically described as limiting passive hip internal rotation, and possibly compressing the underlying sciatic nerve. A traditional method for stretching a tight piriformis is to combine full flexion and external rotation of the hip, typically performed with the knee flexed. Because the piriformis is actually an internal rotator in a position of marked hip flexion, incorporating external rotation into the stretch appears to be a rational approach. In a study on the sacroiliac joint, Snijders et al<sup>42</sup> have shown that cross-legged sitting, which combines flexion and external rotation of the hip, increases the length of the piriformis by 21% as compared to its length in upright standing.

### Hip Internal Rotators

In sharp contrast to the external rotators, no muscle with any potential to internally rotate the hip lies even close to the horizontal plane. From the anatomic position, therefore, it is difficult to assign any muscle as a primary internal rotator of the hip.<sup>17</sup> Several secondary internal rotators exist, however, including the anterior fibers of the gluteus minimus and the gluteus medius, tensor fasciae latae, adductor longus, adductor brevis, pectineus, and posterior head of the adductor magnus<sup>13,17</sup> (FIGURE 5). Note that in contrast to most traditional sources,<sup>26,44</sup> Dostal et al's<sup>17</sup> data listed in TABLE 2 show that the tensor fasciae latae has zero horizontal plane leverage, at least while standing upright in the anatomic position.

Because the overall orientation of the internal rotator muscles is positioned closer to the vertical than horizontal position, these muscles possess a far greater biomechanical potential to generate torque in the sagittal and frontal

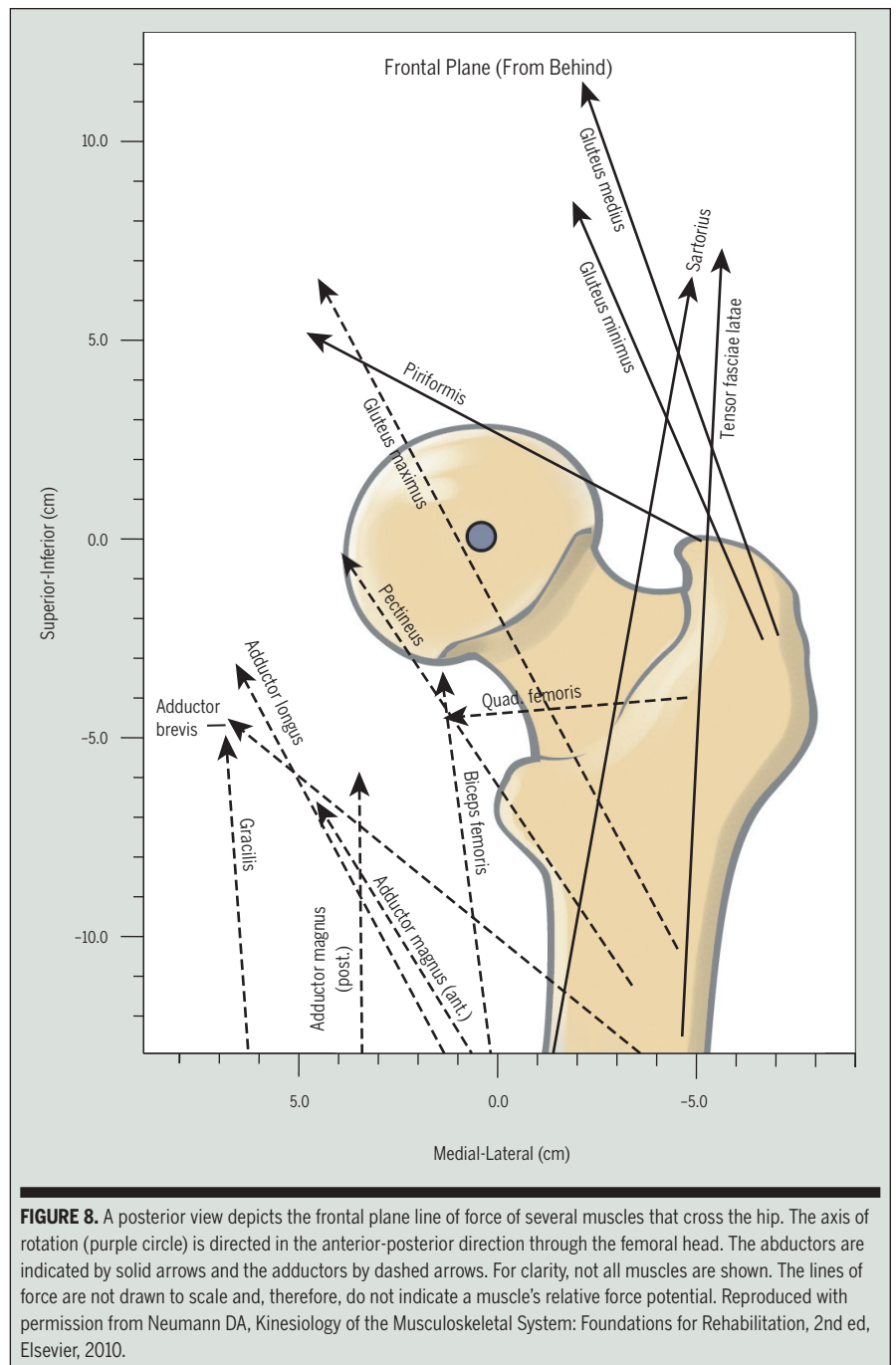


## [ CLINICAL COMMENTARY ]

planes than in the horizontal plane. The rather distinct biomechanical contrast in the rotary potential of the external rotator and internal rotator muscles is curious and interesting. The reasons for the differences may be related to the unique functional demands of human movement (walking, running, or crawling).

With the hip flexed 90°, the internal rotation torque potential of the internal rotator muscles dramatically increases.<sup>13,17,31</sup> With the help of a skeleton model and piece of string, it may be instructive to mimic the line of force of an internal rotator muscle such as the anterior fibers of the gluteus medius. Flexing the hip close to 90° reorients the muscle's line of force from nearly parallel to nearly perpendicular to the longitudinal axis of rotation at the hip. (This occurs because the longitudinal axis of rotation remains nearly parallel with the shaft of the repositioned femur.) **FIGURE 7** shows the changing horizontal plane moment arms for the anterior and posterior fibers of the gluteus medius as the hip is flexed from 0° to 90°. As depicted in **FIGURE 7A**, the anterior fibers are only marginal internal rotators at 0° of flexion, but experience an 8-fold increase in internal rotation leverage by 90° of flexion. Based on these data, an assumed near-maximum contraction force of 200 N of the anterior fibers of the gluteus medius would theoretically produce 1.4 Nm of internal rotation torque at neutral extension but 11.6 Nm of internal rotation torque at 90° of flexion.<sup>13</sup> (In live humans, such a large increase in torque at 90° of flexion may not actually occur due to the potential loss in active peak force created by the shortened muscle fibers.) **FIGURE 7A** indicates that in a position of only 20° to 25° of hip flexion, the internal rotation moment arm of the anterior fibers of the gluteus medius would at least double. Although speculation, an exaggerated anterior pelvic tilt posture could theoretically predispose one to excessive internal rotating posturing of the hip joint.

Surprisingly, very little live human



research could be located that measured the maximal-effort, internal rotation torque throughout a full range of hip flexion. One isokinetic study reported that maximal-effort internal rotation torque in healthy persons increased by about 50% with the hip flexed, as compared to extended.<sup>30</sup> This increased internal rotation torque with flexion may

be due to the increased leverage of some of the internal rotator muscles (such as the anterior fibers of the gluteus medius, as depicted in **FIGURE 7A**), but also to a reversal of rotary action of some of the traditional external rotators, such as the piriformis, or posterior fibers of the gluteus medius (**FIGURE 7B**). The position of hip flexion, therefore, affects the relative

torque potential of both the internal and external rotator muscles, with a global effect of biasing a greater relative increase in internal rotation torque. The actual differences in maximal-effort torque production between the rotator groups at any given point within the range of the sagittal plane motion are not known. Interestingly, **FIGURE 3** shows that the maximal-effort torques are nearly equal for the internal and external rotators; however, the data were collected with the hip flexed to 60°. Maximal-effort contractions from these muscle groups with the hip fully extended should, in theory, result in a significant torque bias that favors the external rotators; although this conjecture cannot be supported by in vivo research.

The clinical significance of an internal rotation torque bias with greater hip flexion has been extensively described in the literature related to the study of the excessively internally rotated and flexed (“crouched”) gait pattern in some persons with cerebral palsy.<sup>13,19</sup> With poor control or weakness of hip extensor muscles, the typically flexed posture of the hip exaggerates the internal rotation torque potential of many muscles of the hip.<sup>2,5,13</sup> This gait pattern may be better controlled by enhanced activation of the external rotator, abductor, and hip extensor muscles. A similar body of research is evolving that suggests a similar pattern of hip muscle weakness may be associated with the pathomechanics of musculoskeletal disorders of the knee, such as patellofemoral joint pain syndrome and noncontact injury to the anterior cruciate ligament in adolescent females.<sup>9,32,49</sup>

## FRONTAL PLANE

### Hip Adductors

**T**HE PRIMARY ADDUCTORS OF THE hip include the pectineus, adductor longus, gracilis, adductor brevis, and adductor magnus (both anterior and posterior heads). Secondary adductors include the biceps femoris (long head), the

gluteus maximus (especially the posterior fibers), quadratus femoris, and obturator externus (**TABLE 2**) (**FIGURE 8**).<sup>16,17</sup>

The primary adductor muscles have relatively favorable leverage for adduction of the hip, averaging almost 6 cm.<sup>17</sup> This leverage is available for the production of adduction torque from both femoral-on-pelvic and pelvic-on-femoral perspectives. Although rigorous study of the adductor muscles highlighting these 2 movement perspectives is lacking in the literature, consider the following possibility. During rapid or complex movements involving both lower extremities, it is likely that many of the adductor muscles are bilaterally and simultaneously active to control both femoral-on-pelvic and pelvic-on-femoral hip movements. Consider, for example, a soccer player firmly planting her left foot as she kicks a soccer ball left-of-center using the right foot. To varying levels, the contracting right adductor muscles are capable of flexing, adducting, and internally rotating the right hip (femur relative to the pelvis) as a way to accelerate the ball in the intended direction. As part of this action, the planted left hip may be actively adducting and internal rotating slightly from a pelvic-on-femoral perspective, driven through concentric activation of the left adductor muscles. Such an action likely also requires eccentric activation of the left gluteus medius, which is well suited to decelerate and control the aforementioned pelvic-on-femoral motions.

In addition to producing adduction torque at the hip joint, the adductor muscles are considered important flexors or extensors of the hip.<sup>17,34</sup> Regardless of hip position, the adductor magnus (especially the posterior head) is an effective extensor of the hip, similar to the hamstring muscles. Most other adductor muscles, however, are considered flexors from the anatomic (extended) position (**TABLE 1**). Once the hip is flexed beyond about 40° to 70° of hip flexion, the line of force of the adductor muscles (except the adductor magnus) appears to cross to the exten-

sor (posterior) side of the medial-lateral axis of rotation of the hip, by which these muscles gain leverage as hip extensors. The specific point at which the adductor muscles change leverage has not been thoroughly investigated, although this concept is discussed in papers by Dostal et al<sup>16,17</sup> and Hoy.<sup>23</sup> Further research, such as that published by Delp et al<sup>13</sup> and Arnold et al,<sup>2-5</sup> is needed to verify more specifically the flexion and extension leverage of the adductors muscles throughout a wide arc of sagittal plane motion.

The bidirectional sagittal plane torque potential of most of the adductor muscles is useful for powering cyclic activities such as sprinting, bicycling, or descending and rising from a deep squat. When the hip is flexed, the adductor muscles are mechanically prepared to augment the other extensor muscles. In contrast, when the hip is closer to full extension, they are mechanically prepared to augment the other hip flexors. The nearly constant triplanar biomechanical demand placed on the adductors muscles throughout a wide range of hip positions may partially explain their relatively high susceptibility to strain injury.

### Hip Abductors

The primary hip abductor muscles include all fibers of the gluteus medius and gluteus minimus, and the tensor fasciae latae (**TABLE 2**).<sup>12</sup> The piriformis, sartorius, and rectus femoris are considered secondary hip abductors. The abductor muscles pass lateral to the anterior-posterior axis of rotation of the hip (**FIGURE 8**).

The gluteus medius is the largest of the hip abductors, accounting for about 60% of the total abductor muscle cross-sectional area.<sup>12</sup> The muscle attaches distally to the lateral and superior-posterior aspects of the greater trochanter.<sup>38</sup> This distal attachment, in combination with its proximal attachments on the upper and more flared portion of the ilium, provides the muscle with the largest abduction moment arm of all the abductor muscles (**TABLE 1**).<sup>17</sup>

The broad, fan-shaped gluteus medius

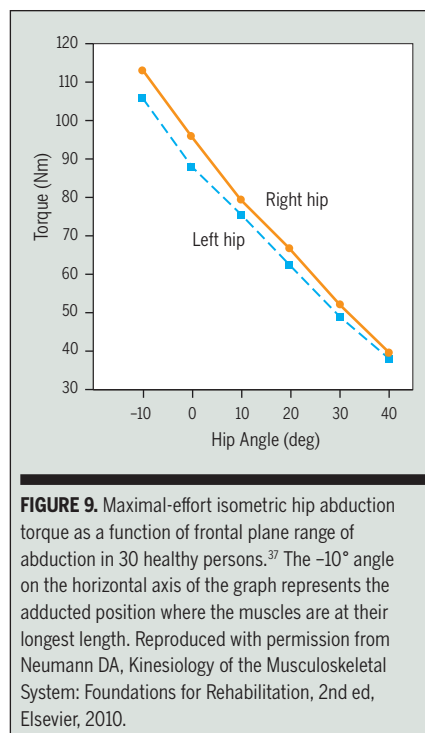
is often subdivided functionally into 3 sets of fibers: anterior, middle, and posterior (TABLE 1).<sup>12,17,43</sup> All fibers contribute to abduction of the hip; however, from the anatomic position, the anterior fibers also produce modest internal rotation and the posterior fibers produce extension and external rotation. As described earlier in this paper, however, the strength and even direction of this muscle's horizontal plane actions can change when the muscle is activated from varying degrees of hip flexion.<sup>4</sup>

The gluteus minimus lies immediately deep and just anterior to the gluteus medius, attaching distally to the anterior-lateral aspect of the greater trochanter.<sup>38</sup> The tendon of the gluteus minimus also attaches to the anterior and superior capsule of the joint.<sup>6,44,47</sup> Perhaps this secondary attachment may help retract the capsule from the joint at the extremes of motion, possibly preventing capsular impingement. Magnetic resonance imaging and other clinical observations suggest that tears or degenerative changes at the point of attachment of the gluteus minimus (and medius) may be a source of pain often and, perhaps, incorrectly diagnosed as trochanteric bursitis.<sup>51</sup>

The gluteus minimus is smaller than the gluteus medius, accounting for about 20% of the total abductor muscle cross-sectional area.<sup>12</sup> Similar to the gluteus medius, the fan-shaped gluteus minimus has been described functionally as possessing 3 sets of fibers.<sup>13,17</sup> All fibers cause abduction, and the more anterior fibers also contribute to internal rotation, most notably when the hip is flexed.<sup>12,29</sup> Some authors consider the posterior fibers as secondary external rotators.<sup>17,43</sup>

The tensor fasciae latae is the smallest of the 3 primary hip abductors, accounting for about 11% of the total abductor muscle cross-sectional area.<sup>12</sup> This muscle arises from the outer lip of the iliac crest, just lateral to the anterior-superior iliac spine. Distally, the tensor fascia latae blends with the iliotibial band.

Contraction of the hip abductor mus-



**FIGURE 9.** Maximal-effort isometric hip abduction torque as a function of frontal plane range of abduction in 30 healthy persons.<sup>37</sup> The  $-10^\circ$  angle on the horizontal axis of the graph represents the adducted position where the muscles are at their longest length. Reproduced with permission from Neumann DA, *Kinesiology of the Musculoskeletal System: Foundations for Rehabilitation*, 2nd ed, Elsevier, 2010.

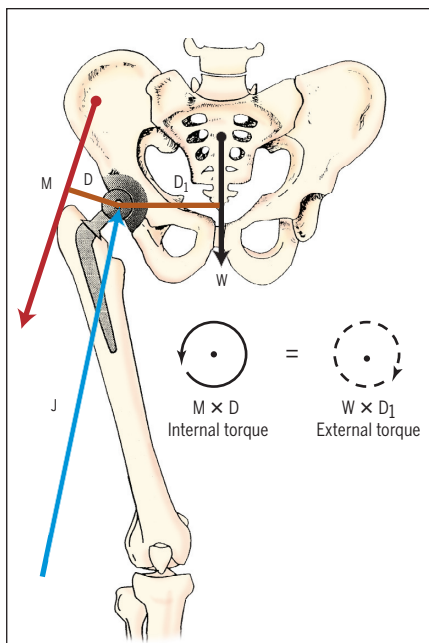
cles with the pelvis stabilized in the frontal plane can produce femoral-on-pelvic hip abduction. Clinically, the torque of an abducting femur is often resisted to measure the abduction torque of the hip abductors as a whole. FIGURE 9 shows a plot of the maximum-effort isometrically produced torque of the right and left abductor muscles in a sample of young healthy adults.<sup>37</sup> Note that the plot is essentially linear, with the least torque produced at  $40^\circ$  of abduction when the muscles are at their near fully shortened (contracted) length. Paradoxically, this position is most often used to manually test the maximal strength of the hip abductors.<sup>26</sup>

FIGURE 9 also shows that the greatest peak hip abductor torque occurs when the abductor muscles are nearly maximally elongated, in a position of  $10^\circ$  of adduction.<sup>37</sup> This frontal plane position corresponds generally to the position of the hip joint when the body is in its single-limb support phase of walking, exactly when these muscles are required to generate frontal plane stability of the hip.

As implied above, the most impor-

tant functional role of the hip abductor muscles occurs during the single-limb support phase of walking. The external (gravitational) adduction torque about the hip dramatically increases within the frontal plane as soon as the contralateral limb leaves the ground.<sup>24</sup> The hip abductors respond by generating an abduction torque about the stance hip that stabilizes the pelvis relative to the femur.<sup>24</sup> In addition, these same muscles may be required to produce a smaller, but at times necessary, internal rotation torque about the stance hip to rotate the pelvis in the same direction as the advancing contralateral “swing” limb. Interestingly, both the gluteus medius and minimus (and possibly the tensor fascia latae) are capable of combining abduction and internal rotation torque at the hip.

The force produced by the hip abductor muscles to maintain frontal plane stability during single-limb support accounts for most of the compressive force generated between the acetabulum and femoral head. This important point is demonstrated by the model in FIGURE 10, which assumes a person is standing only on the stance (right) limb. The moment arm (D) used by the hip abductor muscles is about half the length of the moment arm ( $D_1$ ) used by body weight (W).<sup>37</sup> Given the differences in moment arm lengths, the hip abductor muscles must produce a force (M) about twice that of superincumbent body weight to achieve frontal plane stability while standing on the 1 limb. The acetabulum is pulled down against the femoral head not only by the force of the activated hip abductor muscles, but also by the gravitational pull of body weight. When added, these 2 inferior-directed forces theoretically equal about 2.5 to 3 times one's full body weight.<sup>25</sup> It is noteworthy that about 66% of this force is created by the hip abductor muscles. To achieve static equilibrium about the stance hip, these downward forces are counteracted by a joint reaction force (see “J” in FIGURE 10) of equal magnitude but oriented in nearly the opposite direction as the muscle force. The



**FIGURE 10.** A frontal plane model shows how the force produced by the right hip abductor muscles (indicated in red as M) stabilizes the pelvis while standing only on the right limb. The right hip is shown with a prosthesis. The pelvis-and-trunk are assumed to be in static equilibrium about the right hip. The counterclockwise torque (solid circle) is the product of the hip abductor force (M) times its moment arm (D); the clockwise torque (dashed circle) is the product of superincumbent body weight (W) times its moment arm (D<sub>1</sub>). Because the system is in equilibrium, the torques in the frontal plane are equal in magnitude and opposite in direction:  $M \times D = W \times D_1$ . A joint reaction force (J) is directed through the hip joint. Reproduced and modified with permission from Neumann DA, *Kinesiology of the Musculoskeletal System: Foundations for Rehabilitation*, 2nd ed, Elsevier, 2010.

joint reaction force is directed about 15° from vertical, an angle that is strongly influenced by the line of force of the hip abductor muscles.<sup>25</sup>

The biomechanics described in **FIGURE 10** is based on a person simply standing statically on 1 limb. While walking, however, the joint reaction force is even greater, due to the acceleration of the pelvis over the femoral head. Data based on computer modeling or direct measurements from strain gauges implanted into a hip prosthesis show that joint reaction (compression) forces reach at least 3 times body weight while walking.<sup>24,45</sup>

These forces can increase to 5 or 6 times body weight while running or ascending and descending stairs.<sup>7,45</sup> Even ordinary functional activities or exercises can create joint forces that greatly exceed body weight.<sup>20</sup> Normally, joint forces have important functions, such as stabilizing the femoral head within the acetabulum and providing the stimulus for normal growth and development of the hip in the growing child. Many joint protection principles taught to patients with failing (or potentially failing) biologic or prosthetic hip joints are based on an understanding of the frontal plane biomechanics described in **FIGURE 10**.<sup>1,28,35,36</sup>

## CLOSING COMMENTS

**A**LTHOUGH GREAT STRIDES HAVE been made over the last several decades, there is still much to be learned about how muscles of the hip act in isolation and, especially, in groups. Muscle actions are currently best understood when activated from the anatomic position. What is needed, however, is a greater understanding of how a muscle's action (and strength) changes when activated outside the anatomic position. This knowledge would provide clinicians with a more thorough and realistic appreciation of the potential actions of the muscles that cross the hip. Ultimately, this level of understanding will improve the ability to diagnose, understand, and treat impairments based on the abnormal functioning of hip muscles. ●

**ACKNOWLEDGEMENTS:** *The author would like to thank Jeremy Karman, PT, for his careful review of some of the clinical issues described in this paper.*

## REFERENCES

1. Ajemian S, Thon D, Clare P, Kaul L, Zernicke RF, Loitz-Ramage B. Cane-assisted gait biomechanics and electromyography after total hip arthroplasty. *Arch Phys Med Rehabil*. 2004;85:1966-1971.
2. Arnold AS, Anderson FC, Pandy MG, Delp

3. Arnold AS, Asakawa DJ, Delp SL. Do the hamstrings and adductors contribute to excessive internal rotation of the hip in persons with cerebral palsy? *Gait Posture*. 2000;11:181-190.
4. Arnold AS, Delp SL. Rotational moment arms of the medial hamstrings and adductors vary with femoral geometry and limb position: implications for the treatment of internally rotated gait. *J Biomech*. 2001;34:437-447.
5. Arnold AS, Salinas S, Asakawa DJ, Delp SL. Accuracy of muscle moment arms estimated from MRI-based musculoskeletal models of the lower extremity. *Comput Aided Surg*. 2000;5:108-119. [http://dx.doi.org/10.1002/1097-0150\(2000\)5:2<108::AID-IGS5>3.0.CO;2-2](http://dx.doi.org/10.1002/1097-0150(2000)5:2<108::AID-IGS5>3.0.CO;2-2)
6. Beck M, Sledge JB, Gautier E, Dora CF, Ganz R. The anatomy and function of the gluteus minimus muscle. *J Bone Joint Surg Br*. 2000;82:358-363.
7. Bergmann G, Graichen F, Rohlmann A. Hip joint loading during walking and running, measured in two patients. *J Biomech*. 1993;26:969-990.
8. Blemker SS, Delp SL. Three-dimensional representation of complex muscle architectures and geometries. *Ann Biomed Eng*. 2005;33:661-673.
9. Bolgia LA, Malone TR, Umberger BR, Uhl TL. Hip strength and hip and knee kinematics during stair descent in females with and without patellofemoral pain syndrome. *J Orthop Sports Phys Ther*. 2008;38:12-18. <http://dx.doi.org/10.2519/jospt.2008.2462>
10. Cahalan TD, Johnson ME, Liu S, Chao EY. Quantitative measurements of hip strength in different age groups. *Clin Orthop Relat Res*. 1989;136-145.
11. Carey TS, Crompton RH. The metabolic costs of 'bent-hip, bent-knee' walking in humans. *J Hum Evol*. 2005;48:25-44. <http://dx.doi.org/10.1016/j.jhevol.2004.10.001>
12. Clark JM, Haynor DR. Anatomy of the abductor muscles of the hip as studied by computed tomography. *J Bone Joint Surg Am*. 1987;69:1021-1031.
13. Delp SL, Hess WE, Hungerford DS, Jones LC. Variation of rotation moment arms with hip flexion. *J Biomech*. 1999;32:493-501.
14. Dewberry MJ, Bohannon RW, Tiberio D, Murray R, Zannotti CM. Pelvic and femoral contributions to bilateral hip flexion by subjects suspended from a bar. *Clin Biomech (Bristol, Avon)*. 2003;18:494-499.
15. Dixon MC, Scott RD, Schai PA, Stamos V. A simple capsulorrhaphy in a posterior approach for total hip arthroplasty. *J Arthroplasty*. 2004;19:373-376.
16. Dostal WF, Andrews JG. A three-dimensional biomechanical model of hip musculature. *J Biomech*. 1981;14:803-812.
17. Dostal WF, Soderberg GL, Andrews JG. Actions of hip muscles. *Phys Ther*. 1986;66:351-361.

18. Hansen L, de Zee M, Rasmussen J, Andersen TB, Wong C, Simonsen EB. Anatomy and biomechanics of the back muscles in the lumbar spine with reference to biomechanical modeling. *Spine (Phila Pa 1976)*. 2006;31:1888-1899. <http://dx.doi.org/10.1097/01.brs.0000229232.66090.58>
19. Hicks JL, Schwartz MH, Arnold AS, Delp SL. Crouched postures reduce the capacity of muscles to extend the hip and knee during the single-limb stance phase of gait. *J Biomech*. 2008;41:960-967. <http://dx.doi.org/10.1016/j.jbiomech.2008.01.002>
20. Hodge WA, Carlson KL, Fijan RS, et al. Contact pressures from an instrumented hip endoprosthesis. *J Bone Joint Surg Am*. 1989;71:1378-1386.
21. Hodges PW, Eriksson AE, Shirley D, Gandevia SC. Intra-abdominal pressure increases stiffness of the lumbar spine. *J Biomech*. 2005;38:1873-1880. <http://dx.doi.org/10.1016/j.jbiomech.2004.08.016>
22. Hodges PW, Richardson CA. Contraction of the abdominal muscles associated with movement of the lower limb. *Phys Ther*. 1997;77:132-142; discussion 142-134.
23. Hoy MG, Zajac FE, Gordon ME. A musculoskeletal model of the human lower extremity: the effect of muscle, tendon, and moment arm on the moment-angle relationship of musculotendon actuators at the hip, knee, and ankle. *J Biomech*. 1990;23:157-169.
24. Hurwitz DE, Foucher KC, Andriacchi TP. A new parametric approach for modeling hip forces during gait. *J Biomech*. 2003;36:113-119.
25. Inman VT. Functional aspects of the abductor muscles of the hip. *J Bone Joint Surg*. 1947;29:607-619.
26. Kendall FP. *Muscles: Testing and Function*. 4th ed. Baltimore, MD: Lippincott, Williams & Wilkins; 1993.
27. Khan RJ, Yao F, Li M, Nivbrant B, Wood D. Capsular-enhanced repair of the short external rotators after total hip arthroplasty. *J Arthroplasty*. 2007;22:840-843. <http://dx.doi.org/10.1016/j.arth.2006.08.009>
28. Krebs DE, Elbaum L, Riley PO, Hodge WA, Mann RW. Exercise and gait effects on in vivo hip contact pressures. *Phys Ther*. 1991;71:301-309.
29. Kumagai M, Shiba N, Higuchi F, Nishimura H, Inoue A. Functional evaluation of hip abductor muscles with use of magnetic resonance imaging. *J Orthop Res*. 1997;15:888-893. <http://dx.doi.org/10.1002/jor.1100150615>
30. Lindsay DM, Maitland M, Lowe RC, Kane TJ. Comparison of isokinetic internal and external hip rotation torques using different testing positions. *J Orthop Sports Phys Ther*. 1992;16:43-50.
31. Mansour JM, Pereira JM. Quantitative functional anatomy of the lower limb with application to human gait. *J Biomech*. 1987;20:51-58.
32. McClay Davis I, Ireland ML. ACL injuries--the gender bias. *J Orthop Sports Phys Ther*. 2003;33:A2-8.
33. Mihalko WM, Whiteside LA. Hip mechanics after posterior structure repair in total hip arthroplasty. *Clin Orthop Relat Res*. 2004;194-198.
34. Nemeth G, Ohlsen H. Moment arms of hip abductor and adductor muscles measured in vivo by computed tomography. *Clin Biomech*. 1989;4:133-136.
35. Neumann DA. An electromyographic study of the hip abductor muscles as subjects with a hip prosthesis walked with different methods of using a cane and carrying a load. *Phys Ther*. 1999;79:1163-1173; discussion 1174-1166.
36. Neumann DA. Hip abductor muscle activity as subjects with hip prostheses walk with different methods of using a cane. *Phys Ther*. 1998;78:490-501.
37. Neumann DA, Soderberg GL, Cook TM. Comparison of maximal isometric hip abductor muscle torques between hip sides. *Phys Ther*. 1988;68:496-502.
38. Pfirrmann CW, Chung CB, Theumann NH, Trudell DJ, Resnick D. Greater trochanter of the hip: attachment of the abductor mechanism and a complex of three bursae--MR imaging and MR bursography in cadavers and MR imaging in asymptomatic volunteers. *Radiology*. 2001;221:469-477.
39. Pohntilla JF. Kinesiology of hip extension at selected angles of pelvifemoral extension. *Arch Phys Med Rehabil*. 1969;50:241-250.
40. Richardson CA, Snijders CJ, Hides JA, Damen L, Pas MS, Storm J. The relation between the transversus abdominis muscles, sacroiliac joint mechanics, and low back pain. *Spine*. 2002;27:399-405.
41. Santaguida PL, McGill SM. The psoas major muscle: a three-dimensional geometric study. *J Biomech*. 1995;28:339-345.
42. Snijders CJ, Hermans PF, Kleinrensink GJ. Functional aspects of cross-legged sitting with special attention to piriformis muscles and sacroiliac joints. *Clin Biomech (Bristol, Avon)*. 2006;21:116-121. <http://dx.doi.org/10.1016/j.clinbiomech.2005.09.002>
43. Soderberg GL, Dostal WF. Electromyographic study of three parts of the gluteus medius muscle during functional activities. *Phys Ther*. 1978;58:691-696.
44. Standing S, Gray H. *Gray's Anatomy: the Anatomical Basis of Clinical Practice*. 40th ed. St Louis, MO: Churchill Livingstone; 2008.
45. Stansfield BW, Nicol AC. Hip joint contact forces in normal subjects and subjects with total hip prostheses: walking and stair and ramp negotiation. *Clin Biomech (Bristol, Avon)*. 2002;17:130-139.
46. Urquhart DM, Hodges PW, Story IH. Postural activity of the abdominal muscles varies between regions of these muscles and between body positions. *Gait Posture*. 2005;22:295-301.
47. Walters J, Solomons M, Davies J. Gluteus minimus: observations on its insertion. *J Anat*. 2001;198:239-242.
48. White RE, Jr, Forness TJ, Allman JK, Junick DW. Effect of posterior capsular repair on early dislocation in primary total hip replacement. *Clin Orthop Relat Res*. 2001;163-167.
49. Willson JD, Davis IS. Lower extremity mechanics of females with and without patellofemoral pain across activities with progressively greater task demands. *Clin Biomech (Bristol, Avon)*. 2008;23:203-211. <http://dx.doi.org/10.1016/j.clinbiomech.2007.08.025>
50. Winter DA. *Biomechanics and Motor Control of Human Movement*. Hoboken, NJ: Wiley; 2005.
51. Woodley SJ, Nicholson HD, Livingstone V, et al. Lateral hip pain: findings from magnetic resonance imaging and clinical examination. *J Orthop Sports Phys Ther*. 2008;38:313-328. <http://dx.doi.org/10.2519/jospt.2008.2685>
52. Yoshio M, Murakami G, Sato T, Sato S, Noriyasu S. The function of the psoas major muscle: passive kinetics and morphological studies using donated cadavers. *J Orthop Sci*. 2002;7:199-207. <http://dx.doi.org/10.1007/s007760200034>

 **MORE INFORMATION**  
[WWW.JOSPT.ORG](http://WWW.JOSPT.ORG)

**VIEW Videos on JOSPT's Website**

Videos posted with select articles on the *Journal's* website ([www.jospt.org](http://www.jospt.org)) show how conditions are diagnosed and interventions performed. For a list of available videos, click on **"COLLECTIONS"** in the navigation bar in the left-hand column of the home page, select **"Media"**, check **"Video"**, and click **"Browse"**. A list of articles with videos will be displayed.